

## Original Articles

# Study on pleural effusions due to *Mycoplasma pneumoniae* infection

U K Jayantha<sup>1</sup>

*Sri Lanka Journal of Child Health*, 2005; **34**: 5-6

(Key words: Pleural effusion, *Mycoplasma pneumoniae*)

### Abstract

**Objectives** To find the incidence of pleural effusions among patients with *Mycoplasma pneumoniae* pneumonia.

**Design** Prospective study

**Setting** University paediatric unit, Karapitiya, Galle.

**Method** Patients with pneumonia admitted to university paediatric unit from November 1998 to October 1999 were included. Pleural effusions were confirmed either radiologically or by ultrasound examination. Large pleural effusions causing respiratory distress or persistent effusions were aspirated.

**Results** There were 133 patients with pneumonia. 24 children (14 boys, 10 girls) had *Mycoplasma pneumoniae* pneumonia. All but one were above 4 years of age. Four of the 24 children had pleural effusions. Two effusions were aspirated and were found to be exudates.

**Conclusions** *Mycoplasma pneumoniae* should be considered an aetiological agent in pleural effusions especially when associated with lobar pneumonia

### Introduction

*Mycoplasma pneumoniae* is a common aetiological agent of community-acquired pneumonia in both children and adults<sup>1,2</sup>. It can cause a wide variety of respiratory tract manifestations including acute pharyngitis, bronchitis, bronchiolitis and bronchopneumonia. Pneumonia due to *Mycoplasma pneumoniae* is commonly a mild bronchopneumonia or interstitial pneumonia not requiring hospital admission. Severe lobar pneumonia, lung abscess and pleural effusions are uncommon manifestations<sup>3</sup>.

Adult respiratory distress syndrome is a rare complication of this infection<sup>4</sup>. Pleural effusion is also a recognized manifestation.

---

Senior Lecturer, Department of Paediatrics Faculty of Medicine, Galle.

(Received on 12 May 2004)

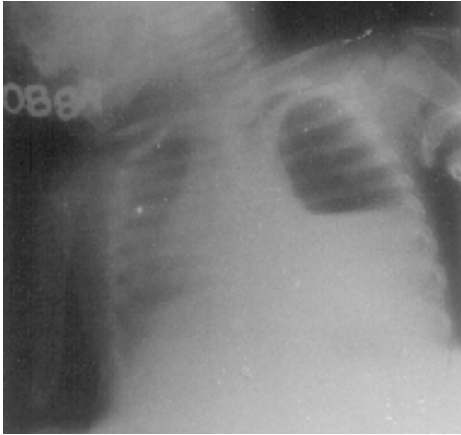
According to Juang *et al* pleural effusion due to *Mycoplasma pneumoniae* pneumonia is 24%<sup>5</sup>. Confluent consolidation without typical lobar pneumonia was seen in 56% of patients. *Mycoplasma pneumoniae* could be isolated from the pleural fluid in some patients with *Mycoplasma pneumoniae* pneumonia<sup>6</sup>. In most instances pleural effusions are self-limiting and recover with antimycoplasma therapy.

### Method

Patients with pneumonia admitted to university paediatric unit from November 1998 to October 1999 were included. Mycoplasma antibody titres were performed in all the patients with pneumonia by using particle agglutination test, in addition to the conventional tests such as full blood count, chest x-ray etc. All patients with serologically proven *Mycoplasma pneumoniae* pneumonia were examined for the presence of pleural effusions. Pleural effusion was confirmed radiologically and by ultrasound examination. Consent was obtained from parents. Ethical approval for the study was obtained from the Ethics Committee of the Faculty of Medicine. Mycoplasma serology was tested by particle agglutination test done at Micro-biology Department, Faculty of Medicine, Galle.

### Results

There were 133 patients with pneumonia seen from November 1998 to October 1999. 105 patients had lobar pneumonia, 28 patients had interstitial and/or bronchopneumonia. 19 patients (11 boys, 8 girls) with lobar pneumonia were due to *Mycoplasma pneumoniae*. Mycoplasma antibody titres ranged from 640-20,480. 18 of them were above 4 years. 4 of the 19 had pleural effusions (Figure 1). Pleural fluid aspiration was done in 2 patients. Analysis of pleural fluid showed presence of exudates (table 1). 3 effusions were diagnosed radiologically and one mild effusion was diagnosed by ultrasound examination. 5 children (3 boys, 2 girls) with interstitial pneumonia had *Mycoplasma pneumoniae* aetiology. None of them had pleural effusions.



**Figure 1.** Left sided pleural effusion due to *Mycoplasma pneumoniae*.

**Table 1**  
**Analysis of pleural fluid in patients with *Mycoplasma pneumoniae* pneumonia**

Patient No	Proteins (g/l)	Cells (per cu mm)
1	09	Polymorphs 60 Lymphocytes 180
2	07	Polymorphs 42 Lymphocytes 54

### Discussion

*Mycoplasma pneumoniae* is a common aetiological agent in childhood pneumonia. According to Albeit *et al* *Mycoplasma pneumoniae* pleural effusions are uncommon and tend to occur with a severe illness<sup>6</sup>. In most instances pleural effusions are mild and resolve with the antimycoplasmal therapy. It can rarely lead to respiratory distress requiring aspiration of pleural fluid. In our study 4 (16%) out of 24 patients with *Mycoplasma pneumoniae* pneumonia had pleural effusions. Pleural fluid, aspirated in 2 patients due to respiratory distress and persistent fever, showed the presence of an exudate. High protein content and the presence of inflammatory cells (polymorphs and lymphocytes) were seen in both samples of pleural fluid. Subsequent follow up of these patients with pleural effusions was uneventful. According to some studies *Mycoplasma pneumoniae* had been isolated from the pleural fluid<sup>7</sup>. Study by Nagayama *et al* found 56 patients with *Mycoplasma pneumoniae* pleural effusions among 773 patients with *Mycoplasma pneumoniae* infection<sup>8</sup>. Polymerase chain reaction (PCR) seems to be the best way to diagnose *Mycoplasma pneumoniae* pleural effusions<sup>9</sup>. In the absence of this facility, diagnosis of *Mycoplasma pneumoniae* pleural effusion could be made in the presence of high

*Mycoplasma* antibody titre in association with synpneumonic pleural effusion. Microparticle agglutination test is a highly specific and sensitive serological test<sup>10</sup>.

### Conclusions

Syn-pneumonic pleural effusions are commonly seen with bacterial pneumonia. According to the results of this study about 16% of *Mycoplasma* lobar pneumonia patients had syn-pneumonic effusions. Therefore *Mycoplasma pneumoniae* has to be considered an aetiological agent in children with pleural effusions especially when associated with lobar pneumonia.

### References

1. Ruuskanen O, Nohynek H, Ziegler T, Capeding R, et al. Pneumonia in childhood: etiology and response to antimicrobial therapy. *Eur J Clin Microbiol Infect Dis* 1992; **11**(3): 217-23.
2. Dy S. Community acquired pneumonia in adults. *West J Med* 1994; **161**(4): 383-89.
3. Chiou CC, Liu YC, Lin HH, Hsieh KS. *Mycoplasma pneumoniae* infection complicated by lung abscess, pleural effusion, thrombocytopenia and DIC. *Paediatr Infect Dis J* 1997; **16**(3): 327-29.
4. Van-Bever HP, Van-Doorn JW, Demey HF. Adult respiratory distress syndrome associated with *Mycoplasma pneumoniae* infection. *Eur J Pediatr* 1992; **151**(3): 227-28.
5. Juang YC, Chiang YC, Tsao FC, Lan RS, et al. *Mycoplasma pneumoniae* pneumonia. *Chang Keng I Hsueh* 1991; **14**(3): 156-62.
6. Powell DA. *Mycoplasma pneumoniae*. In: Behrman RE, Kliegman R M, Jenson H L, editors. *Nelson textbook of Paediatrics*. 16th ed. Philadelphia: Saunders, 2000; 914-15.
7. Loo VG, Richardson S, Quinn P. Isolation of *Mycoplasma pneumoniae* from pleural fluid. *Diagn Microbiol Infect Dis* 1991; **14**(5): 443-45.
8. Nagayama Y, Sakurai N, Yamamoto K. Clinical observations of children with pleuropneumonia due to *Mycoplasma pneumoniae*. *Pediatr Pulmonol* 1990; **8**(3): 182-87.
9. Narita M, Matsuzono Y, Itakura O, Yamada S, Togashi T. Analysis of mycoplasmal pleural effusion by the polymerase chain reaction. *Arch Dis Child* 1998; **78**: 67-9.
10. Echevarria JM, Leon P, Lopez TA. Diagnosis of *Mycoplasma pneumoniae* infection by microparticle agglutination and antibody-capture enzyme immunoassay. *Eur J Clin Microbiol Infect Dis* 1990; **9**(3): 217-20.

9. Narita M, Matsuzono Y, Itakura O, Yamada S, Togashi T. Analysis of mycoplasmal pleural effusion by the polymerase chain reaction. *Arch Dis Child* 1998; **78**: 67-9.
10. Echevarria JM, Leon P, Lopez TA. Diagnosis of *Mycoplasma pneumoniae* infection by microparticle agglutination and antibody-capture enzyme immunoassay. *Eur J Clin Microbiol Infect Dis* 1990; **9**(3): 217-20.

